



Preoperative misdiagnosed gastrointestinal stromal tumor surgical “transferred” into gastric duplication cyst

Preoperativno pogrešno dijagnostikovani gastrointestinalni stromalni tumor hirurški „preveden” u duplikacionu cistu želuca

Ranko Lazović*, Brigita Smolović†, Ljiljana Vučković‡, Miodrag Radunović*

Clinical Center of Montenegro, Surgery Clinic, *Center for Digestive Surgery, Clinic of Internal Medicine, †Department for Gastroenterohepatology, ‡Center for Pathology and Forensic Medicine, Podgorica, Montenegro

Abstract

Introduction. Gastrointestinal duplications are rare congenital anomalies, especially in the adult population which can occur along the entire gastrointestinal tract. The rarest among them are gastric duplications, making up 2–8% of all gastrointestinal duplications. Unusual embryonic malformations can be found even in the adult population and should always be considered in the differential diagnosis of thoraco-abdominal tumors. Unclear findings during preoperative diagnostic procedures are the reason for presenting the case. **Case report.** We present a 33 years old female, with tumorous lesion in the stomach wall, which had the endoscopic ultrasound features of gastrointestinal stromal tumor. During surgery, it was determined that the lesion was actually a cystic formation with gelatin content and histological examination confirmed the diagnosis of gastric duplication cyst. **Conclusion.** Preoperative diagnosis of gastric duplication cyst has always been a challenge for clinicians, since its morphological appearance may vary. That is the reason why these anomalies are often misdiagnosed as solid tumorous lesions by imaging methods and even by the most superior ones, and set up the surgery as a part of diagnostic algorithm.

Key words:

gastrointestinal stromal tumors; stomach; cysts; diagnosis, differential; digestive system surgical procedures; treatment outcome.

Apstrakt

Uvod. Gastrointestinalne duplikature su retke kongenitalne anomalije naročito u odrasloj populaciji koje mogu nastati duž čitavog gastrointestinalnog trakta. Najređe su želudačne duplikature koje čine 2–8% svih gastrointestinalnih duplikatura. Neobične embrionalne malformacije mogu se naći i u odrasloj populaciji i zbog toga bi uvek trebalo da budu razmotrene u diferencijalnoj dijagnozi torako-abdominalnih tumoroznih promena. Nejasni nalazi dobijeni tokom preoperativne dijagnostike su razlog prezentacije ovog slučaja. **Prikaz bolesnika.** Prikazali smo pacijentkinju, staru 33 godine sa tumoroznom promenom u zidu želuca koja je prema endoskopsko-ultrazvučnim karakteristikama izgledala kao gastrointestinalni stromalni tumor. Intraoperativno je ustanovljeno da je promena u stvari cistična formacija sa želatinoznim sadržajem, a histološkim pregledom je potvrđena dijagnoza želudačne duplikacione ciste. **Zaključak.** Preoperativna dijagnoza želudačnih duplikacionih cista je uvek izazov za kliničare. Morfološki izgled ovih duplikatura je različit. To je razlog da se ove anomalije *imaging* metodama, čak i onim najsuperiornijim, pogrešno dijagnostikuju tako da se time hirurgija premešta u sastavni deo dijagnostičkog algoritma.

Ključne reči:

gastrointestinalni stromalni tumori; želudac; ciste; dijagnoza, diferencijalna; hirurgija digestivnog sistema, procedure; lečenje, ishod.

Introduction

Gastrointestinal duplications are rare congenital anomalies, with an incidence of 1 in 4,500 births¹, and are very rare in the adult population. They can be formed along the entire gastrointestinal tract, but the least common are gastric du-

plications, making up 2–8% of all gastrointestinal duplications². The most common symptoms are epigastric pain or discomfort, vomiting, loss of weight, rarely bleeding. Due to the absence of symptoms, they are usually discovered incidentally during upper endoscopy and endoscopic ultrasound or other abdominal imaging methods, performed from

other reasons^{3,4}. Diagnosis of these cystic duplicatures before surgery is complicated due to mimicry with other diseases. Differential diagnosis includes gastrointestinal stromal tumor (GIST), neuroendocrine tumor, pancreatic heterotopy, pancreatic pseudocyst and neurogenic tumor^{4,5}. There may be unusual complications such as recurrent pancreatitis or biliary fistula, chronic inflammation, formation of local peptic ulceration inside the cyst, obstruction, and rarely rupture/perforation or compression of the surrounding structures^{2,6}. Although extremely rare, malignant transformation of these lesions is also possible⁴⁻⁶. Accurate diagnosis is confirmed by surgery, followed by histopathological examination⁷. There are several methods of treating gastric duplication cysts, however enucleation with minimal disruption of normal anatomy, can be considered as the first choice procedure.

In the case under review here, the tumorous lesion of the gastric wall is presented, presurgically appeared as GIST, while during the surgery it appeared as cystic formation. The diagnostic algorithm is also discussed, regarding preoperative misleading and unclear findings.

Case report

A thirty-three years old female patient turned to gastroenteropathologist to determine the cause of pain below the right costal arch, nausea and vomiting. Previous medical history was unremarkable. Physical examination was normal, as well as laboratory analyzes. Abdominal ultrasound was normal as well. Serology, i.e. IgG antibodies for *Helicobacter pylori* with ELISA method were positive (13.1 U/L; negative for <5.0). The eradication therapy lasted ten days, however there was no improvement at all. A year later, due to persistent complaints, esophagogastroduodenoscopy was performed and showed a protruding mass, 2 cm in size, localized in cardia, near gastroesophageal junction, with intact mucosa.

In diagnostic algorithm, a multislice computed tomography (MSCT) (16 slice) was performed, and clearly formed tumorous mass in gastric wall was found, circa 2 cm in size, with intact surrounding organs, but without possibility to differentiate if the mass was solid or cystic (Figure 1).

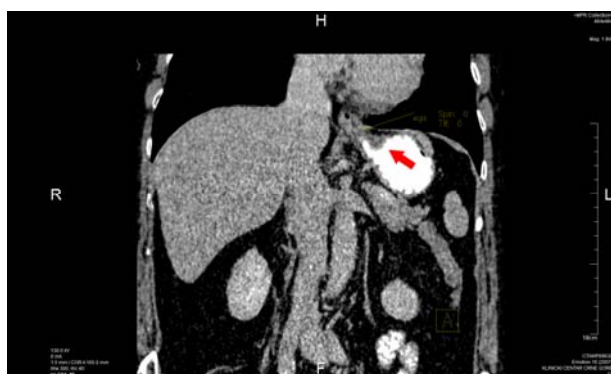

Fig. 1 – Multislice computed tomography (MSCT) with contrast showed unclear picture of tumorous lesion (red arrow) in gastric wall, near esophagogastric junction.

Endoscopic ultrasonography (EUS) with 7.5 and 12 MHz probe, showed hypoechoenic, homogeneous lesion

2.5 × 1.5 cm in diameter, which belonged to the fourth gastric wall layer, near the gastroesophageal junction (Figure 2).

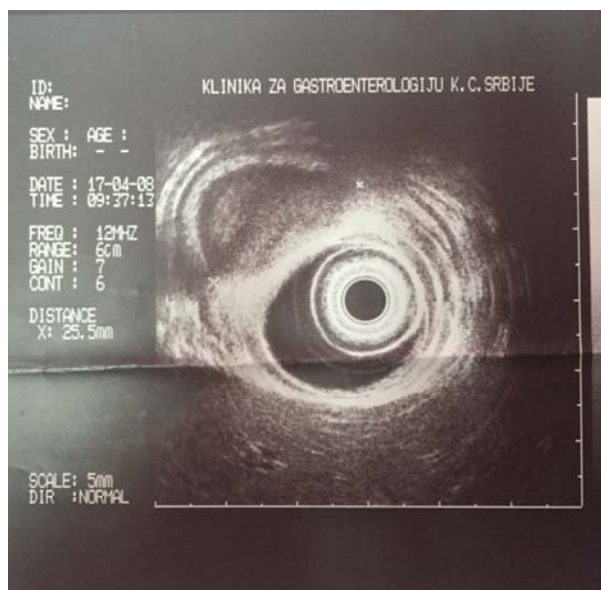


Fig. 2 – Endoscopic ultrasonography shows hypoechoenic, homogenous lesion belonging to the fourth gastric wall layer near gastroesophageal junction.

Based on the EUS characteristics, GIST was suspected. During the open surgery, the protruding mass was removed entirely, and noted that it has a cystic formation, with a gelatinous whitish content inside. Histopathological examination of the resected gastric wall was covered by smooth mucosa with preserved folds. On the section, the specimen had a recognizable stratification, with cystic formation in the muscle layer, without communication with the surface of the stomach wall, nor with peritoneum. The cyst had a smooth internal surface and it was filled with dense, light brown liquid content. Histology: surface was covered by corpus type mucosa; within the muscle layer there was a cystic formation, covered by squamous epithelium with stratification, pseudostratified ciliary epithelium, and single row cylindrical epithelium (parts which were covered with single-row cylindrical epithelium had the morphology of gastric type of mucosa). The cyst contained mucus, erythrocytes and macrophages. The wall of the cystic formation was made of mucosa, submucosa and muscle layer. In some parts lamina muscularis mucosae was incorporated into the muscle layer of the stomach wall (Figure 3).

The postoperative course of the patient was without complications.

Discussion

Preoperative diagnosis of gastric duplication cysts is always a challenge. Gastric duplication cysts are the rarest among gastrointestinal duplications, and among elderly usually asymptomatic.

In most of the cases, as it was in our report, the lesion is localized in the upper part of the stomach: in the level of the cardia, close to the cystic formation 20 mm in diameter junction, on the front or back wall of the fundus^{7,8}.

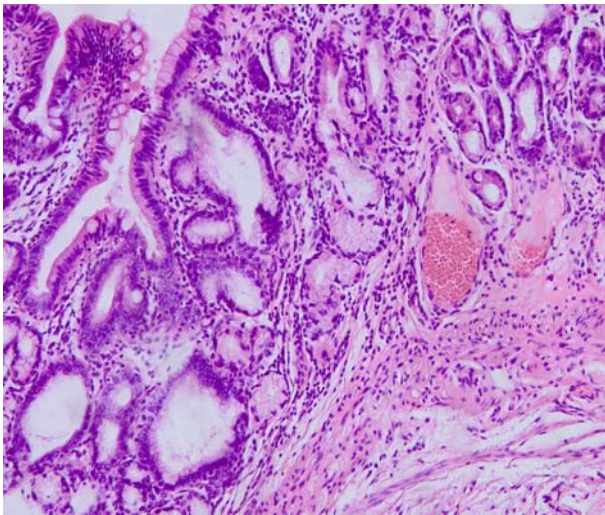


Fig. 3 – Mucus, single row cylindrical epithelium (gastric type) of mucosa covering one part of the cyst wall). [Hematoxylin-eosin (HE) staining, ×100].

Abdominal ultrasound, computed tomography and magnetic resonance imaging are useful diagnostic methods^{4, 6, 7}. However, in presented case, the abdominal ultrasound did not show the existence of the cyst, since MSCT image was not useful for determination if the mass was solid or cystic. Literature data shows that MSCT may indicate the presence of solid instead of cystic lesions in the 43% to 70% of cases⁸. The explanation may be related to the different amount of highly concentrated proteins in the cystic content which may be appeared as solid tumor⁹. It is often difficult to distinguish gastric duplication cysts from other subepithelial changes in the gastric wall because the morphological appearance of the cysts varies. The finding depends on the density of its content. The cysts that contain solid, thick secretions are often misdiagnosed as a solid mass by imaging techniques. EUS is also superior to computed tomography in the differentiation of cystic and solid masses⁸. Both methods may be useful for determining the localisation, size and affecting the surrounding structures¹⁰. EUS is useful in determination intramural versus extramural gastric lesions¹¹. However, the accuracy of EUS findings is greatly affected by intracystic content – cystic lesions with thick mucoid content most often are diagnosed as GIST, which is the most common subepit-

helial lesion^{3, 8, 12}. This occasion happened in presented report. Based on the findings of EUS, the patient was surgically treated under the suspicion that tumorous lesion was GIST. Certainly, we must not forget that the GIST can be presented as cystic degeneration as well. Also, fine needle aspiration biopsy is not recommended in any suspicious case on GIST, because of the risk of peritoneal dissemination.

Communicating gastric duplications usually do not require intervention if both lumens (the cystone, and the gastric one) are connected, unlike non-communicating duplications that require surgical treatment².

Our report states that the correct diagnosis was confirmed by surgical intervention, which has been emphasized in the literature as well⁷.

Gastric duplication cysts are often diagnosed during surgery in elderly patients, but histology still remains the most important method for determination of the tissue of origin of the duplication cyst. The essential characteristic of gastric duplication cysts is that the wall is surrounded by at least one layer of smooth muscle, covered by mucous membrane, which contains gastric epithelium in most cases¹.

Laparoscopic surgery was not an option for us, since the cyst was situated near vagal nerve and its branches whose injury would cause serious complication and urge to extend surgical procedure.

Every subjective patient's complains disappeared after surgical recovery. Control endoscopies performed once per year in next two years, as well as clinical appearance showed normal finding.

Conclusion

Despite the progress in diagnostic imaging methods, including endoscopic ultrasound, preoperative diagnosis of gastric duplication cysts in the adult population is still difficult and challenging due to their rarity in one hand, and the absence of specific findings on the other hand. Cystic lesion with dense mucoid content may be misdiagnosed as GIST. It is important to emphasize that unusual embryonic malformations can occur in the adult population and therefore must be considered in the differential diagnosis of thoraco-abdominal tumorous lesions.

REFERENCES

1. *Laskowska K, Gatazka P, Daniluk-Matras I, Leszczynski W, Serafin Z.* Use of diagnostic imaging in the evaluation of gastrointestinal tract duplications. *Pol J Radiol* 2014; 79: 243–50.
2. *Di PM, Curcio G, Marrone G, Milazzo M, Spada M, Traina M.* Gastric duplication associated with pancreas divisum diagnosed by a multidisciplinary approach before surgery. *World J Gastroenterol* 2010; 16(8): 1031–3.
3. *Deesomsak M, Asnakul P, Junyangdikul P, Prachayakul V.* Rare adult gastric duplication cyst mimicking a gastrointestinal stromal tumor. *World J Gastroenterol* 2013; 19(45): 8445–8.
4. *Sultan M, Karanovic D, Chalhoub W, Ajmera A, Manjra F, Zeck JC, et al.* Gastric Duplication Cyst With Elevated Amylase: An Unusual Presentation Mimicking Pancreatic Cystic Neoplasm. *ACG Case Rep J* 2015; 2(2): 86–8.
5. *Kim SM, Ha MH, Seo JE, Kim JE, Min BH, Choi MG, et al.* Gastric duplication cysts in adults: A report of three cases. *J Gastric Cancer* 2015; 15(1): 58–63.
6. *Singh JP, Rajdeo H, Bhuta K, Savino JA.* Gastric duplication cyst: Two case reports and review of the Literature. *Case Rep Surg* 2013; 2013: 605059.
7. *Tjendra Y, Lyapichev K, Henderson J, Rojas CP.* Foregut duplication cyst of the stomach: A case report and review of the literature. *Case Rep Pathol* 2016; 2016: 7318256.
8. *Napolitano V, Pezzullo AM, Zeppa P, Schettino P, D'armiento M, Palazzo A, et al.* Foregut duplication of the stomach diagnosed by endoscopic ultrasound guided fine-needle aspiration cytology: Case report and literature review. *World J Surg Oncol* 2013; 11: 33.

9. *Malekboseini SA, Moradian F.* Gastric Duplication Cyst in a man Presenting with Elevated Liver Enzymes and Icterus. *Iran J Med Sci* 2014; 39(2 Suppl): 228–31.
10. *Samona S, Berri R.* A case report and review of the literature of adult gastric duplication cyst. *Case Rep Surg* 2015; 2015: 3. ID 240891.
11. *Song YX, Chen XW, Wang ZN.* Case Report: A mass seen under gastroscopy "disappeared", during laparotomy. *Int J Clin Exp Med* 2015; 8(4): 6308–10. eCollection 2015.
12. *Geng YH, Wang CX, Li JT, Chen QY, Li XZ, Pan H.* Gastric foregut cystic developmental malformation: Case series and literature review. *World J Gastroenterol* 2015; 21(2): 432–8.

Received on November 2, 2015.

Revised on May 11, 2016.

Accepted on June 1, 2016.

Online First October, 2016.